

The Role of Cytology, Colposcopy and Colposcopic Directed Biopsies in the Evaluation of Unhealthy Cervix

Krishnaveni Avula¹, Jyothirmai², Arige Sushruth Kumar³, Arige Subodh Kumar⁴

Abstract

Introduction: In India, unhealthy cervix is a common finding on per speculum examination and it is recommended to do the cervical cytology to detect any epithelial cell abnormality. **Aim:** To correlate the finding in 100 women with unhealthy cervix by cytology, colposcopy and colposcopically directed biopsies. **Materials and Methods:** A total of 100 patients with unhealthy cervixes on speculum examination were evaluated by cytology, colposcopy and colposcopic directed biopsies. **Results:** The colposcopy was more sensitive (96%) than the cytology (44%) where as its specificity was only 76% compared to 90% on cytology. 60% of the patients with abnormal colposcopy had dysplasia and malignancy on HPE. 63% of the patients with positive cytology had dysplasia on HPE. So, the predictive value of both the tests were comparable. The false negative result of colposcopy was only 1% compared to 18% for cytology, whereas false positive rates were almost the same for both the tests. **Conclusions:** Colposcopy in an excellent extended gynecological examination tool for the evaluation.

Keywords: Cytology; Cervix Colposcopy.

Introduction

Carcinoma cervix is the most frequent of all genital tract cancers and after the breast, the second most common site of malignancy in

females. Incidence varies from 20-40% per 1,00,000 women, as reported by the various cancer registries [1,2,3]. In most parts of the developed world, this figure has come down to less than 10%. Hence, in India the goal remains to control the disease and decrease incidence by at least half. In India, annually over 90,000 cases are reported with this disease and 70-80% are diagnosed in the advanced stage [4] and the incidence of carcinoma cervix is 15.4-46.5 per 1,00,000 women. Among developing countries, it is the leading cause of virally induced cancer, worldwide in females. In the industrialized world, cervical is a relatively uncommon event ranking 10th. In developed countries 80% are cured because of early detection, however, in developing countries 80% are incurable at the time of detection. The principle reason for the discrepancy is the wide spread availability of screening for cervical cancer in the industrialized nations. Approximately, 50% of all women in the industrialized world have had at least one pap smear during a 5 year period, in contrast to 5 percent in developing countries [2]. Invasive cancer of cervix has been considered a preventable cancer because of easy accessibility of the cervix to inspection, has a long pre-invasive track, availability of cervical cytology screening programs and effective treatment for pre-invasive lesions.

In highly screened population, the incidence rate of cervical cancer has dropped by 70-90% and also remarkable lowering of staging and mortality- down staging of the disease. Cervical cancer best exemplifies for the dictum prevention is better than cure. The approach proposed for India and other developing countries without the laboratory facilities and resources to envisage cytological screening of all adult women is called as down - staging.

¹Assistant Professor,
Department of Obstetrics
and Gynecology, Gandhi
Medical College,
Secunderabad, Telangana
500003, India.

²Retired Professor,
Department of Obstetrics
and Gynecology, Kurnool
Medical College, Kurnool,
Andhra Pradesh 518002,
India.

³III Year MBBS Student,
Gandhi Medical College,
Secunderabad, Telangana
500003, India.

⁴Professor and HOD,
Department of Plastic
Surgery, Gandhi Medical
College, Secunderabad,
Telangana 500003, India.

Corresponding Author:
Krishnaveni Avula,
Assistant Professor,
Department of Obstetrics
and Gynecology,
Gandhi Medical College,
Secunderabad, Telangana
500003, India
E-mail:
akveni1010@gmail.com

Received on 03.11.2018,
Accepted on 14.11.2018

In many developing countries, 50-60% of carcinoma cervix could be detected in stage 0-stage 1a by down staging. Hence clinical down staging is an interim strategy [3]. In India cytological evaluation of cells obtained from the cervix by pap smear was followed by a dramatic reduction in the incidence of cervical cancer. Colposcopy is the diagnostic test to evaluate patients with an abnormal cervical cytological smear of abnormally appearing cervix. The pap smear, colposcopy and colposcopy directed biopsy are the three methods by which cervix can be studied for evidence of early malignant changes. Colposcopy is a study of the subtle changes in the vascular pattern of the cervix while cytology is the study of the morphological changes in the cell. When utilized alone, colposcopy has an accurate rate 80%, while cytology has a false negative rate of 2-20%. When used together the accuracy of diagnosis increases to 98.9%.

Therefore, in the present study 100 women who were in reproductive age and who attended the gynaecology out patient at Government general hospital, Kurnool and whose cervixes were noted to be unhealthy on clinical examination were subjected to cytology, colposcopy, and colposcopic directed biopsies, where-ever needed and the results were analyzed.

Materials and Methods

The present study was done over a period of one and half years from 1st July 2006 to September 2007. In the present study, 100 women who attended the gynecological out patient at government general hospital, Kurnool, and whose cervixes were noted to be unhealthy clinically were subjected to cystoscopy and directed biopsies.

Inclusion Criteria

1. Age group of women 45 yrs.
2. Marital status: married women only
3. Pregnancy was excluded in all women
4. Oral contraceptive pill usage was excluded.
5. Presenting symptoms included in the study were
 - a. Leucorrhoea
 - b. Pain abdomen
 - c. Dyspareunia
 - d. Irregular menses
 - e. Post coital bleeding

f. Prolapse uterus.

6. All the women were examined in post menstrual period.

Detailed history regarding age, age at marriage, age at consummation of marriage, religion, parity, age of first pregnancy, menstrual history, presenting symptoms were taken and were noted down in the proforma appended. A detailed clinical gynaecological examination was performed. Wet smear was taken for microscopic study at the time of speculum examination. Subsequently, colposcopy examination was conducted in all these cases.

The requirements for colposcopy are as follows;

1. Equipment - Instruments
 - a. Colposcope
 - b. Cusco's bivalve self-retaining speculum.
 - c. Endocervical curettage
 - d. Ayre's spatula
 - e. Cervical punch biopsy forceps.
2. Chemical Agents;
 - a. Normal Saline
 - b. 5% Acetic acid
 - c. Lugol's Iodine - composition - Crystalline - 1.2-2grams, Potassium Iodine 4 grams, distilled water 100ml.
 - d. Cytology fixative - Koplín's jar
 - e. 10% Buffered formalin solution.
3. Others
 - a. Examination table
 - b. Cotton tipped applicator
 - c. Steel tray with cover to keep sterilized instruments
 - d. Sterilizer
 - e. Consent forms and histo-pathological examination-requisition forms and proforma were taken.

Colposcopy

The colposcope on a rolling stand was used with focal length of 300mm. It consists of

- a. The binocular microscope on a swing arm incorporating a magnification changer.
- b. A versatile stand so designed as to allow easy manipulation and comfortable observation.

The microscope consists of the binocular head with eye pieces, the main objective, the focusing

mechanism, the microscope tilting mechanism, the illuminating system and built in filters. The magnification changer permits quick changes of magnification by turning the knurled head without changing the positive of the objective or the eyepiece and thus different magnifications can easily be obtained. The stand is a long vertical hollow tube of stainless steel, fixed on a heavy cast iron base fitted with study castors, which render the movement smooth. A swinging arm to which the microscope is attached slides freely up and down the vertical column. The microscope is balanced to counter weight moving inside the hollow stand. The swinging arm can be rotated about in and out with ease and can be locked in any position by clamping screws.

Procedure Followed for Examination

1. The patients are placed comfortably on the examination table in the dorsal position. The external genitalia were examined with naked eye to exclude any vulval pathology or any discharge from the introitus. Bi-valved self-retaining speculum is introduced carefully to prevent contact bleeding from the cervix.
2. Presence of mucous and character of discharge were noted. A vaginal wet-smear was taken and microscopic examination for trichomonas vaginalis and moniliasis was conducted. Using the ayres spatula, ectocervix and squamous columnar junction was lightly scraped by turning it through 360 degrees and the material is transferred onto a slide. Specimen spreading was done in such a way as to achieve a single cell thickness uniformly dispersed over a large area. Smear were then immediately fixed in a solution and sent for pap's staining.
3. The cervix is than examined in illuminated light through the colposcope with focal length adjusted. Normal saline was used to remove the thick and excessive mucous, if present, and abnormal areas noted. 5% acetic acid was then applied to the ectocervix with the help of cotton wool swab sticks. The effect is seen within 10 to 30 seconds and lasts for 30-40 seconds. The squamous epithelium, columnar epithelium, their junction and the transformation zone were observed and the abnormal areas were noted. Acetic acid application is repeated, whenever necessary.
4. For better visualization of angio-neuritic structure, the green filter was used. The green filter absorbs red from color spectrum, thus causing the blood vessels to stand out as black structure against a background of white or translucent epithelium.

5. Cotton wool swab soaked in lugol's solution was applied to the cervix and vagina and negative areas noted. Colposcopically guided wedge biopsy using a knife with a no. 22 blade was performed from the abnormal areas noted. The tissue was fixed in a solution of 10% formal saline.

The universal stain for cytological preparations is the papanicolaou stain. Harri's hematoxylin is the optimum nuclear stain and combination of OG6 and EA 50 give the subtle range of green, blue and pink hues to the cell cytoplasm. The staining times can be adjusted to suit personal preference for a darker or paler stain. Alternatives to Scott's tap water substitute include 0.1% of ammoniated water or a weak aqueous solution of lithium carbonate.

The nuclei should appear blue/black

Cytoplasm

Non-keratinizing squamous cell blue/green

Keratinizing cells pink/orange

Results

Hundred women with unhealthy cervixes on speculum examination included in this study were selected for pap smear, colposcopy and colposcopic directed biopsy. The patients age ranged from 18-45 years.

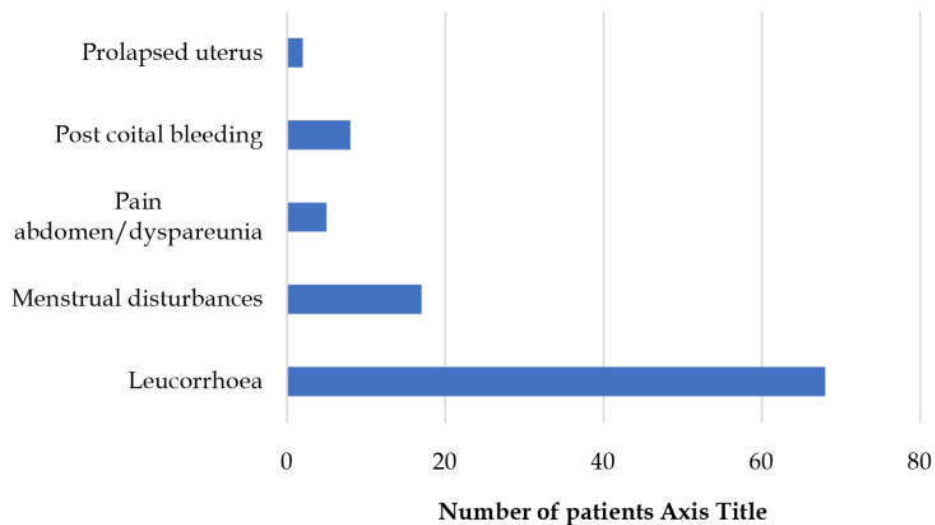
Forty (40)% of the patients belonged to the age group between 30-39 years. 53% of the women were between para 3-4, 34% of the patients were those who were less than 2 para, 10% of the women para 5 and above, while 3% were nulliparous women. 83% of the patients were Hindus. Majority of the patients were class 5 who constituted 51%. 55% of the patients got married at an age of less than 19 years., 42% got married between 20-29 years of age and only 3% of the patients got married at an age of age of more than 30 years. (Table 1)

Sixty eight (68)% of the patients presented with leucorrhoea, 17% presented with menstrual disturbances, 8% gave history of post-coital bleeding, 5% presented with pain abdomen and 2% had prolapsed uterus. Some of these patients had more than one complaint, in whom the major symptom was taken into consideration. (Figure 1).

Seventy five (75)% of the patients showed inflammation on cytology. The severest of the lesions was considered when more than one lesion was noticed. Atypical transformation zone was noted to be abnormal in 40% of the cases. In 95% of the cases,

Table 1: The distribution of patients in study

Age group	No of patients	Percentage
<19	6	6%
20-29yrs	35	35%
30-39 yrs.	40	40%
40-49 yrs.	19	19%
Parity		
Nulliparous	3	3%
<2	34	34%
>2-<4	53	53%
5& above	10	10%
Religion		
Muslims	14	14%
Hindus	83	83%
others	3	3%
Socio-economic class		
Class -1-professionals	-	-
Class 2-white collared job holders	2	2%
Class 3-skilled workers	14	14%
Class 4-semi-skilled	33	33%
Class 5-unskilled	51	51%
Age at marriage		
<19yrs	55	55%
20-29yrs	42	42%
>30yrs	3	3%

**Fig. 1:** Presenting symptoms in present study

Acetowhite epithelium was seen. In 40% of the cases, punctuations were seen, while mosaic patients was seen in 15%. In 2% of the cases, there was no acetowhite epithelium, instead only atypical vessels were seen. This may be because in infection, which might have led to loss of epithelium. 40% of the patients showed atypical TZ on colposcopy, 23% showed cervico-vaginitis, 18% showed squamous metaplasia, 10% had normal appearance on colposcopy, while 3% showed invasive carcinoma.

Ectropion without metastasis was seen in 3%, erosion in 2% and condyloma in 1% of the cases. (Table 2).

Cervical biopsy chronic non-specific cervicitis in 45% of the cases, normal histology in 14%, mild dysplasia in 12% non-specific endocervicitis in 9%, severe dysplasia in 7%, moderate dysplasia in 5% invasive carcinoma in 3%. (Table 3).

Atypical TZ was seen in 63.2% of the patients, who patients who were between 40-45 years of age.

Table 2: Cytology and Colposcopy Observations

Cytology Observations	No of cases	Percentage
Normal smear	6	6%
Inflammatory	75	75%
Mild dysplasia/atypia	12	12%
Moderate dysplasia	2	2%
Severe dysplasia	5	5%
Positive for malignancy	-	-
Analysis of atypical transformation zone		
Acetowhite epithelium	38	95%
Punctuation	16	40%
Mosaic	6	15%
Atypical vessels	3	7%
Colposcopy Findings		
Normal	10	10
Invasive carcinoma	3	3
Cervico-vaginitis	23	23
Squamous metaplasia	18	18
Ectropy	3	3
Erosion	2	2
Condyloma	1	1
Atypical TZ	40	40
Total	100	100

Table 3: Colposcopic guided cervical biopsy the followed finding

Microscopic observations	No of patients	Percentage
Normal histology	14	14%
Chronic non-specific cervicitis	45	45%
Non-specific endocervicitis	9	9%
Hyperplasia stratified squamous epithelium	3	3%
Mild dysplasia/ koilocytic change	12	12%
Moderate dysplasia	5	5%
Invasive carcinoma	3	3%
Severe dysplasia	7	7%

Atypical TZ was seen in 49.4% of Hindus. Dysplasia on Cytology was noticed in 19.3% of Hindus and 21.4% of Muslims. Dysplasia on biopsy was found in 27.7% of the Hindus and in 7.1% Muslims. Malignancy on biopsy was detected in 3.6% of the Hindus. Amongst the multipara, 43.4% had atypical transformation zone, 22.7% had dysplasia on Cytology and 24.6% had dysplasia on biopsy and 1.9% had malignancy on HPE. In the grand multipara group, 80% had abnormal transformation zone, 30% had dysplasia on cytology, 40% dysplasia on HPE and 20% had malignancy on HPE. Atypical TZ was seen in 14.3% of class 3 patients, 54.5% of class 4 patients and 45.1% of class 5 patients. Dysplasia on Cytology was seen in 14.3% of class 3, 18.2% of class 4, and 21.6% of class 5 patients. Dysplasia on biopsy was noticed in 14.3% of class 3, 27.3% of class 4, and 25.5% of class 5 patients. Malignancy on biopsy was found in 3.3% of class 4 and in 3.9% of class 5 patients. Typical TZ was seen in 25.6% of the patients who got married between 20-29 years of age, in 56.9% of the

patients who got married at an age of less than 19 years. Dysplasia on cytology was seen in 10.3% of the cases who got married between 20-29 years of age and in 25.9% of the cases who got married at less than 19 years of age. Dysplasia on biopsy was seen in 7.7% of those who got married between 20-29 years of age and in 36.2% of those who got married at less than 19 years of age. Malignancy was detected in 5.2% of patients who got married at an age of less than 19 years. (Table 4).

Among the cases who presents with leucorrhoea, 19% had abnormal cytology, 44% had atypical transformation zone, 29.4% had dysplasia and 1.47% of the cases had malignancy. Atypical transformation zone was seen in 47.1% of the patients who had presented with menstrual disturbances and dysplasia on cytology was seen in 17.6% and dysplasia on biopsy was seen in 17.6% of the patients who had menstrual disturbances. Amongst those with post-coital bleeding (8%), 37.5% had abnormal cytology, 50% had atypical transformation zone, 12.5% had

Table 4: The incidence in the various age groups with colposcopic findings

Age	Number of patients with abnormal findings	Atypical TZ Number of cases(%)	Dysplasia on cytology Number of cases (%)	Dysplasia on biopsy Number of cases (%)	Malignancy on biopsy Number of cases (%)
<19	6	-	-	-	-
20-29	(35)9	8(22.9%)	5(14.3%)	5(14.3%)	-
30-39	(40)26	23(57.5%)	9(22.5%)	12(30%)	1(2.5%)
40-49	(19)12	12(63.2%)	5(26.3%)	7(36.8%)	2(10.5%)
Religion					
Muslim	14(3)	2(14.3%)	3(21.4%)	1(7.1%)	-
Hindus	83(44)	41(49.4%)	16(19.3%)	23(27.7%)	3(3.6%)
Others	3(-)	-	-	-	-
Parity					
Nulliparous	3	1(33.3%)	-	-	-
1-2	34	11(32.4%)	4(11.8%)	7(20.6%)	-
3-4	53	23(43.4%)	12(22.7%)	13(24/6%)	1(1.9%)
5&above	10	8(80%)	3(30%)	4(40%)	2(20%)
Socio economic status					
1	-	-	-	-	-
2	-	-	-	-	-
3	2	2(14.3%)	2(14.3%)	2(14.2%)	-
4	19	18(54.5%)	6(18.5%)	9(27.3%)	1(3.3%)
5	26	23(45.1%)	11(21.6%)	13(25.5%)	2(3.9%)
Age at marriage					
<19yrs	58	33(56.9%)	15(25.9%)	21(36.2%)	3(5.2%)
20-29yrs	39	10(25.6%)	4(10.3%)	3(7.7%)	-
>30yrs	3	-	-	-	-

Table 5: Presenting symptoms vs dysplasia, atypical T-Z biopsy

Symptoms	No of cases	Atypical T-Z	Dysplasia on cytology	Dysplasia on HPE	Malignancy on HPE
Leucorrhoea	68	30(44.1%)	13(19.1%)	20(29.4%)	1(1.5%)
Menstrual disturbances	17	8(47.1%)	3(17.6%)	3(17.6%)	-
Postcoital bleeding	8	1(20%)	3(37.5%)	1(17.6%)	2(25%)
Pain abdomen/dyspareunia	5	14(20%)	-	-	-
Prolapsed uterus	2	-	-	--	-

Table 6: Validity of colposcopy with colposcopic guided biopsies (HPE) in the diagnosis of dysplasia and malignancy

Colposcopy	HPE positive	HPE negative
Positive	26(a)	17(b)
Negative	1	56(d)
Total	27	73

Sensitivity = $a/a+c=26/27=96\%$, Specificity = $d/b+d=56/73=76\%$
 Predictive value = $a/a+b=26/43=60\%$, False positive = $b/a+b=17/43=39\%$
 False negative = $c/c+d=1/57=1\%$, Uncorrected χ^2 value-(42.86) = $p<0.001$.
 Corrected - (39.94)- $p<0.001$. highly significant

dysplasia and 25% of the cases had malignancy. (Table 5).

In the study, out of 27 cases of colposcopic directed biopsy proven dysplasia and malignancy, 26 cases were correctly diagnosed as malignancy by colposcopy. One case, which was diagnosed as cervicitis by colposcopy, came as mild dysplasia with koilocyte

atypia on HPE. Hence colposcopy had higher sensitivity (96%) and low false negative rate (1%). 60% of the patients with abnormal colposcopy had dysplasia on HPE. (among the 43 patients of abnormal colposcopy, 26 patients were diagnosed as having dysplasia and malignancy on HPE. (Table 6).

Table 7: Validity of cytology with colposcopic directed biopsies (HPE) in the diagnosis of dysplasia and malignancy

Pap smear	HPE positive	HPE negative
Positive cytology	12	7(b)
Negative cytology	15	66(d)
Total	27	73

Sensitivity= $a/a+c = 12/27=44\%$
 Specificity = $d/b+d=66/73=90\%$
 Predictive value= $a/a+b=12/19=63\%$
 False positive= $b/a+b=7/19=36\%$
 False negative= $c/c+d=15/81=18\%$
 Uncorrected 'value - (15.56)- $p<0.001$
 Corrected - (13.38) - $P<0.001$.

Table 8: Validity of cytology with colposcopy in the diagnosis of dysplasia and malignancy

Pap smear	Positive colposcopy	Negative colposcopy
Positive	16(a)	3(b)
Negative	27	54(d)
Total	43	57

Sensitivity= $a/a+c=16/43=37\%$
 Specificity= $d/b+d=54/57=94\%$
 Predictive value= $a/a+b=16/19=84\%$
 False positive= $b/a+b=3/19=15\%$
 False negative= $c/c+d=27/81=33\%$
 Uncorrected 'value-(16.25)- $p<0.001$
 Corrected - (14.24)- <0.001 -significant

In the present study, we observed the sensitivity of cytology to be about 44% . Specificity of cytology was high (90%), when compared to that on colposcopy (76%). 63% of the patients with abnormal cytology had dysplasia on HPE. (Among the 19 patients who were positive on cytology, 12 patients were positive on HPE for dysplasia) (Table 7).

When cytology was compared with colposcopy, cytology had only 37% sensitivity. On the other hand, cytology showed higher specificity (94%). (among the 57% of the patients with negative colposcopy, 54 patients were negative on cytology too). Cytology had less false positive rate (15%). The false negative rate on cytology was however high (33%). (Table 8).

Discussion

Cancer of the uterine cervix is the most common cancer in women in developing world. 80% of all the cases of cancer cervix occur in developing countries. India accounts for 18% of them. High risk factors like teenage pregnancy, multiparty, low socio-economic status etc. are responsible for high incidence of invasive cancer (20-45/1,00,000 women) in our country [4]. 75% of the cases are diagnosed in the late stages, and no curative treatment is possible in

them, leading to high morbidity and mortality. Pap's smear colposcopy and colposcopic guided biopsies are methods for cervical cancer screening. These are simple outpatient procedures done without anesthesia. Pap-smear gives a warning that there is malignancy in the genital tract and colposcopy pin-points abnormalities with early malignant change, thereby target biopsies can be taken.

Erosion of cervix is one of the most common finding in the outpatient department. It may be the eversion of the endocervical mucosa or superficial ulceration (true erosion), which may be due to malignancy. In most of the cases, it is difficult to differentiate clinically between true erosion and eversion of endocervical mucosa (ectropion) which is normal. In these cases, therefore cytology, colposcopy and colposcopic directed biopsy can play an important role to detect early pre-invasive, pre-clinical cervical cancer.

Theoretically, the only accurate way of evaluating false negative cytology, would be to perform conization in all patients, even in those with normal cytology findings and to study the one in several sections. Obviously, this cannot be done. The void is filled by colposcopic directed biopsies, which can detect those cases missed by cytology. Simultaneous use of colposcopic, results in no

significant loss of time, because it merely replaces the speculum examination. The exact site of biopsy can be spotted reducing the incidence of repeated biopsy. In negative cytology, colposcopy can dispose of suspicious basis of clinical examination, reducing further number of unnecessary biopsies. Further colposcopy can enable us to perform target cytology smears from the suspicious areas. Colposcopy is the only procedure, available at present for the in-vivo study of the blood vessels of the cervix. The vascular pattern of the cervix represents one of the important diagnostic criteria of colposcopy.

Castle PE, et al. [5] have recently reported 25% of cases of HPV dysplasia, CIS, in patients with persistent inflammatory smears, through colposcopy and colposcopic directed biopsies. Colposcopy also helps in identification of false positive, false negative smears. Colposcopy is an ideal setting for triage of patients with abnormal smears, as a complement to cytology. In case of abnormal smear, colposcopy identifies appropriate site for biopsy and identifies exact location of diseased tissue, so, the size of biopsy is adopted to the lesion with great precision. Colposcopic directed biopsies are cost-effective in comparison to cone biopsies. We can mark the size, shape, topography and grading of lesion by colposcopy. We can resort to more conservative management, leading to less hysterectomies and more therapeutic conizations. The ultimate goal is to diagnose preinvasive, pre-clinical carcinoma of cervix. There is no infallible method for screening the cervical lesion. Cytology, colposcopy and cervical biopsies have their own advantages and disadvantages in detecting the pre-invasive, pre-clinical carcinoma of cervix. They are complementary to each other. Hence, the combined simultaneous use of all three techniques can pick-up early cases which may be missed by any single method.

Taking into account, the combined value of cytology, colposcopy and colposcopic directed biopsies, we screened 100 cases of clinically unhealthy, cervixes at the outpatient department of obstetrics and gynecology, Kurnool medical college, Kurnool, irrespective of their symptoms in the reproductive age group. After explaining the procedure and screening methods, the women who had unhealthy cervixes clinically and who were willing were taken up for this study. Those women who were pregnant, those on oral contraceptive pills, who had hysterectomies, and those with clinical evidence of cervical growth were excluded from this study. Histopathological examination of colposcopic directed biopsy specimen is taken as reference diagnosis. Biopsy was Performed even in

negative colposcopy to avoid missing malignancy in cytology and histopathological examination were done. In the present study, maximum patients (59%) were in the group of 30-45 years, 83% belonged to the Hindu religion and 84% belonged to class 4 and class 5 socioeconomic status, 63% were multi and grandmulti parous. 55% were married below the age of 19 years, most common presenting symptom was leucorrhoea (68%), most common cytological observation was inflammatory (75%), most common colposcopic finding was aceto-white epithelium (38%). Most common vascular pattern was punctuation, and most common histological observation was chronic non-specific cervicitis (45%).

In the present study, leucorrhoea was the major presenting symptom and was noted in 68% of the cases, 8% of the patients had post-coital bleeding, 17% had mensural irregularities, 5% had pain abdomen and 2% of the patients had prolapsed uterus. These results were similar to the study done by P.R Handa et al. [6].

In the present study, on evaluation of 100 cases of unhealthy cervixes by means of cytology, 6% of the cases were normal, 75% of the cases showed inflammatory smear, 19% had dysplasia, and there were no positive cases of malignancy. The results of the present study are similar to the study done by Krishna algotar [7] and Wills Sheila [8]. In Krishna algotar's 5.7% cases showed normal smear, 77.14% had inflammatory smears, 15.7% cases had dysplasia and 1.43% were positive for malignancy. In Will Sheila study, 80% of the cases showed inflammatory smear, and 20% were dysplasia's.

In this study there were different observations from that of PR Handa et al. [6], V.R Ambiye and PR Vaidya [9]. In P.R Hand et al. [6] study, 35.6% of the cases were normal, 56.4% were inflammatory, 2.4% were dysplasia's and 0.2% of the cases were positive for malignancies. In V.R Ambiye and P.R Vaidya's [9] study - 19.3% of the cases showed normal smear, 54% of the cases inflammatory, 23.6% were dysplasia's and 3.3% of the cases were positive for malignancy.

The disparity in cytological findings between the different studies may be due to inadequate sampling, inadequate fixation, obscuring elements, technical variability in the quality of smears, and inter observer variability.

In this study, colposcopic findings were normal in 10%, aceto-white epithelium was seen in 38%, abnormal vasculature was seen in 25%, invasive carcinoma in 3% cervico-vaginitis was present in 23%, squamous metaplasia was seen in 18%, ectropy was found in 3%, and comndyloma was seen in 1%.

The present results does not match that of VR Ambiye & P.R. Vaidya et al. [9], Phatak Satish & Bharani bharati et al. [10]. In the study by V.R. Ambiye et al. [9] group, 10% had normal findings, 46.6% had aceto-white epithelium, 6.6% had abnormal vasculature, 3.6% had cervico- vaginitis, 3% had ectropy, 6% squamous metaplasia and 19.3% had erosions. In the study by Bharani bharati et al.[10], normal was seen in 31%, aceto-white epithelium was seen in 36%, abnormal vasculature in 15%, cervico-vaginitis in 3%, ectropy in 17%, and squamous metaplasia in 51%. This could be to the variability in the assessment of colposcopic findings where experience is required and may be due to the variation in the study group which was involved. (Table 9).

In this study the histopathology observations showed normal histology in 14%, 45% had chronic non-specific cervicitis, 9% had endocervicitis, 12% had mild dysplasia, 5% had moderate dysplasia, 7% had sever dysplasia and 3% had invasive carcinoma. These findings of this study correlate with the findings of Wills Sheila et al. [8] and that of Algotar et al. [7]. In this study, colpohistopathological correlation is found to be 96%. It is not correlating with that of Krishna algotar [7]- 81.3%., however, it is correlating with that of Wills Sheila-92% [8]. (Table 10).

Colposcopy had high false positive rate (39%). This may be because of over- estimation of colposcopic impression and very immature metaplasia can sometimes appear atypical and may be difficult to distinguish from dysplasias. Cervicitis may also sometimes present as aceto-white epithelium with fine punctuations. Specificity of colposcopy was less (76%), when compared to sensitivity. False positive rate is a little less in this study on cytology (36%), when compared to that on colposcopy (39%). False negative rate on cytology was about 18% and was higher than on colposcopy (1%). Low sensitivity (44%) higher false negative rate (18%) may be due to infections, inadequate sampling, improper fixation, obscuring elements, etc. (Table 11).

In this study, colpohistopathological correlation was found to be at 96%. It is correlating with the studies of Wills shiela et.al and Stafl and Matingly, but not correlating with the study of Krishna algotar. (Table 12).

Cytohistological correlation obtained in this study is 44% considerably lower than the colpohistological correlation of 96%. The error in collection technique, fixation, obscuring elements, and also the presence of infection and tissue necrosis interfere in correct cytology reading. In the present study, cytology was under -reported in some of the high-grade lesions

Table 9: Colposcopy findings in comparision with other studies

Findings	VR Ambiye & PR Vaidy ⁹	Phatak satish& Bharani bharati et al ¹⁰	Present study
Normal	10%	31%	10%
Aceto-white epithelium	46.6%	36%	38%
Abnormal vasculature	6.6%	15%	25%
Frank invasive	-	-	3%
Cervico-vaginitis	3.6%	3%	23%
Ectopy	3%	17%	3%
Squamous metaplasia	6%	51%	18%
True erosion	19.3%	-	2%
unsatisfactory	-	-	-

Table 10: Histopathology analysis in comparision with other studies

Microscopic observations	Wills Sheila ⁸	Nagarkatti R S ⁹	Algotar ⁷	Present study
Normal			5.7%	14%
Chronic cervicitis	49.1%	39.2%	64.3%	54%
Dysplasia	27.6%	19.5%	15%	24%
Invasive cancer	0.21%	3.9%	5.7%	3%

Table 11: Comparitive study colposcopy and cytology

Colposcopy	Krishna algotar ⁷	Singh dastur nanavathi ¹¹	Present study
False positive	7.1%	60.42%	39%
False negative	24.2%	1.92%	1%
Cytology			
False positive	8.5%	63.64%	36%
False negative	7.6%	17.98%	18%

Table 12: Colpohistopathological Correlation

Study	Correlation
Stafli & Matingly ¹²	85%
Wills shiela et.al ⁸	92%
Dastur, Singh, nanawati ¹¹	96%
Krishna algotar ⁷	81.3%
Present study (2007)	96%

(high rate of false negatives – 18%) as compared to the colposcopy (false negative rate-1%). False positive rate in cytology (36%), are comparable to that on colposcopy (39%). Same observation has been reported by Krishna algotar [7], in their studies. It also confirms high sensitivity of colposcopic directed biopsies. Cytohistological correlation in my study (44%) matches with that of Bharati et al. [10] study (51%) but different from Krishna algotar's [7] study (58.8%). This difference in the correlation values could be because of errors in collection technique, inadequate sampling, inter-observer variabilities.

In this study, cyto-colposcopic agreement is about 37% and it does not match with the studies of Dastur, Singh, nanawati et al. [11], where it is 96% and with that of Krishna algotar [7] where it is 81.3%. This may be problem due to over-estimation of colposcopic impressions and inadequate sampling, fixation, obscuring elements, infection different in study group. (Table 13).

Table 13: Cytohistopathological correlation

Study	Correlation
Dastur, Singh, nanawati ¹¹	20%
Krishna algotar ⁷	58.8%
Bharati et.al ¹⁰	51%
Present study (2007)	44%

Conclusion

A combined cytological, colposcopic evaluation is preferred, since it is highly accurate in predicting the degree of severity of the lesion. Cytology with colposcopy showed an accuracy of 37% but cytology with colposcopic directed biopsies showed correlation of 44%, in detecting dysplasia and malignancy, thus cytology and colposcopy complement each other ideally. Colposcopy is an important tool which complements cytology and histopathology in detection of various cervical lesions.

In contrast to cytology, colposcopy has not achieved worldwide acceptance, as a cancer

screening modality, due to inherent cost, and a need for wide availability of expertise. It is most often being used to evaluate patients with abnormal cytology. The draw-back of colposcopy lies in possible over-interpretation and overtreatment of low-grade lesions which otherwise regress in majority (80%) with a risk of progression to invasive cancer in only 1% of cases. HPV DNA typing has emerged as a triage procedure to find out these patients with low-grade lesions who have potential to progress to invasion.

In evaluating the cases with unsatisfactory colposcopy and picking up of glandular lesions. endo-cervical curettage, conization, if indicated are helpful in these cases. Recently new sets of colposcopic criteria have been recommended to identify the glandular disease such as location over columnar epithelium, large glands, patchy red and white coloration and abnormal vessels.

Colposcopy in an excellent extended gynecological examination tool for the evaluation of the female genital tract. Errors in its interpretation can be avoided with experience and by following a proper protocol of examination. Advantages of colposcopy weigh over its limitations. Hence colposcopy should be encouraged along with routine cytology screening and all biopsies should be colposcopic directed biopsies in future.

References

1. World Health Organization (WHO). Human Papillomavirus Infection and Cervical Cancer. 2010. Available from: http://www.who.int/vaccine_research/diseases/hpv. (Last accessed on 2016 Feb 10).
2. Ferlay J, Soerjomataram I, Ervik M, Dikshit R, Eser S, Mathers C, et al. GLOBOCAN 2012;0. Cancer Incidence and Mortality Worldwide: IARC Cancer Base No. 11. Lyon, France: International Agency for Research on Cancer; 2013 (Last accessed on 2016 Jan 27).
3. Goldie SJ, Gaffikin L, Goldhaber-Fiebert JD, Gordillo-Tobar A, Levin C, Mahe C. Alliance for Cervical Cancer Prevention Cost Working Group. Cost-effectiveness of

- cervical cancer screening in five developing countries. *N Engl J Med.* 2005;353:2158-68.
4. Gakidou E, Nordhagen S, Obermeyer Z. Coverage of cervical cancer screening in 57 countries: low average levels and large inequalities. *PloS Med.* 2008;5:e132.
 5. Castle PE, Stoler MH, Solomon D, Schiffman M. The relationship of community biopsy-diagnosed cervical intraepithelial neoplasia grade 2 to the quality control pathology-reviewed diagnoses: an ALTS report. *Am J Clin Pathol.* 2007;127:805-15.
 6. Handa PR, Dhall GI. Colposcopy as diagnostic aid in cases of suspicious cervix. *J Obstet Gynaecol.* 1991; 41(6):785-92.
 7. Algotar K, Nalawade A, Dhanawat DG. Balloon Mitral Valvuloplasty: Maternal and Foetal Outcome. *Bombay Hospital Journal* 2004;47:03.
 8. Wills S, Azhagammai, Kanthamani PN. Histo-cyto-colposcopic evaluation of 39 cases of postmenopausal bleeding. *The Journal of Obstetrics and Gynaecology of India* 1991;41:99-102.
 9. Nagarkatti RS, Ambiyer VR, Vaidya PR. Rupture uterus: changing trends in etiology and management. *J Postgrad Med [serial online]* 1991 [cited 2018 Oct 26];37:136.
 10. Bharani Bharti, Phatak Satish R. Feasibility and yield of endometrial biopsy using suction curette device for evaluation of abnormal pre and postmenopausal bleeding: *J Obstet Gynecol India*, 2008 Jul-Aug;58(4):322-26.
 11. Sukhpreet L Singh, Nayana A Dastur, Murari S Nanavati. A comparison of colposcopy and papanicolaou smear : sensitivity, specificity and predictive value: *Bombay Hospital Journal.* 2000 Jul; 42(3):447-51.
 12. Staff A, Mattingly RE. Colposcopic diagnosis of cervical neoplasia. *Obstet Gynecol* 1973;41:168.
-